

Algoritmo per una lesione palpabile presente nella donna in premenopausa

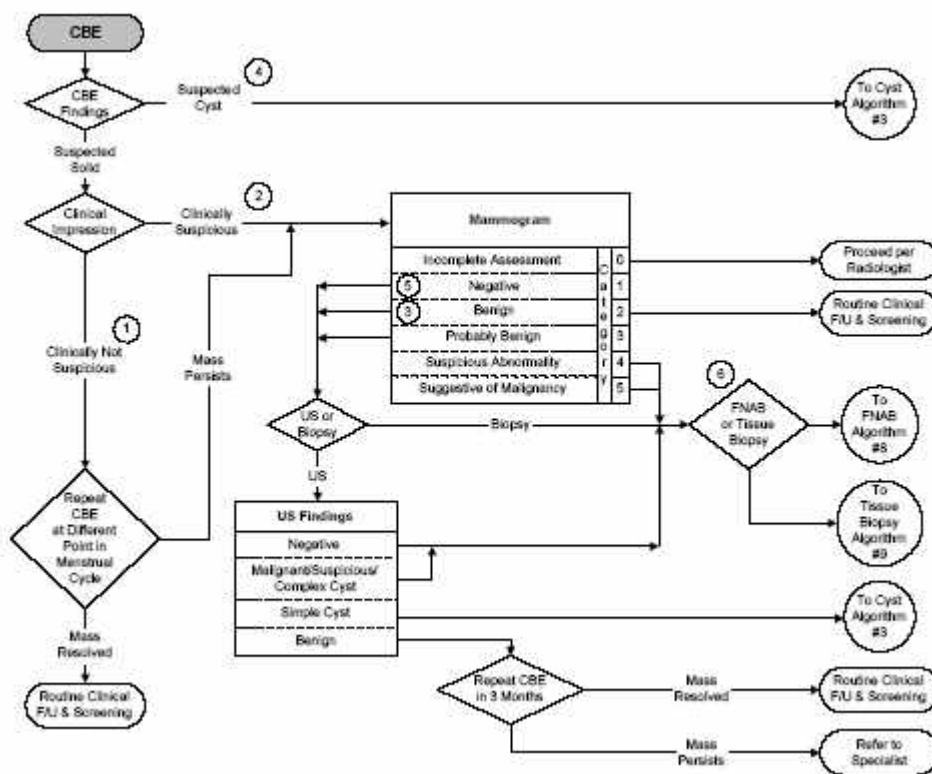
Clinical Breast Protocols Workgroup

May 2000 Revised Second Edition

California Department of Health Services, Cancer Detection Section

Publisher: University of California – Davis

www.sdsu.edu/qap



note all' algoritmo

Please note that wherever "mass resolved" directs the reader to "routine clinical follow-up and screening", this direction applies only when the rest of the exam is normal and there are no other symptoms. Otherwise the reader should go to the appropriate algorithm.

- ① Clinically benign masses such as fibroadenomas are classically rubbery and mobile. Prominent glandular tissue is generally mirrored in the contralateral breast. These signs are suggestive of benignity, but they are not diagnostic.
- ② A clinically suspicious mass may have one or more features consistent with cancer: feeling firm or hard, irregular, solitary, and different from the surrounding breast tissue. Sometimes such masses are fixed and associated with other signs such as skin retraction. However, any asymmetrical finding may be a cause for concern.
- ③ Mammography can be performed using a radiopaque marker on the skin over a palpable lesion to help determine if the lesion corresponds to the mammographic lesion. A non-corresponding mammographic finding may represent a separate lesion which needs further work-up.
- ④ When the clinician suspects that the mass is cystic, it is reasonable to proceed directly to aspiration in premenopausal women (or postmenopausal women who have had a mammogram within six months). Ultrasound is the imaging method of first choice in younger women <30 years of age. Ultrasound can help distinguish solid from cystic masses. However, even ultrasound has limitations in making this distinction. Mammography can be used to further define the mass, although mammograms in younger women can be difficult to interpret due to increased tissue density. Neither ultrasonography nor mammography are diagnostic of malignancy; malignancy can only be confirmed through FNAB cytology or tissue biopsy. FNAB implies cytological examination of the cells obtained by aspiration of the lesion (with several passes of the needle) using a fine needle (22 gauge or smaller). FNAB should be performed by health professionals trained and experienced in the technique.
- ⑤ A negative mammogram should not deter the clinician from arranging FNAB or tissue biopsy of a palpable mass, since around 18 percent of mammograms are normal in the presence of a palpable cancer.
- ⑥ FNAB is optional if another type of biopsy is planned. FNAB may assist in patient counseling and planning the surgical approach. However, a negative FNAB does not preclude proceeding with excisional biopsy/definitive surgery. See Algorithm 8 for managing results of FNAB and Algorithm 9 for managing results of tissue biopsy. If interpretation of the mammogram, CBE or FNAB are discordant (disagree), consider referring for tissue biopsy.